

Original Research Article

Spectrum of Testicular FNAC in Infertile Males : A Study of 50 Cases in a Tertiary Medical Centre in North India

Kaneeka Bhatnagar¹, Pavneet Kaur², Vikram Narang³, Harpreet Kaur⁴¹Senior Resident, ²Professor, ³Assistant Professor, ⁴Professor, Department of Pathology, Dayanand Medical College and Hospital, Ludhiana, Punjab 141001, India.

Abstract

Corresponding Author:

Kaneeka Bhatnagar, Senior Resident, Department of Pathology, Dayanand Medical College and Hospital, Ludhiana, Punjab 141001, India.

E-mail: dr.kaneeka@gmail.com

Received on 15.04.2019,

Accepted on 20.05.2019

Background: Testicular FNAC is a simple and an inexpensive method for evaluation of testicular pathology including inflammatory, non-neoplastic and neoplastic conditions and now has gained popularity as a diagnostic and therapeutic modality in management of male infertility. Assessment of spermatogenesis in azoospermic males is important in the diagnosis of infertility and being a minimally invasive and cost effective method, it gives an insight into the various factors leading to azoospermia. *Aims & Objectives:* To assess spermatogenesis on testicular FNAC and to determine causes of male infertility in azoospermic males. *Methods and Materials:* The study was conducted in 50 azoospermic infertile males in the Department of Pathology. Detailed history of the patient, hormonal levels and ultrasound findings were taken into account wherever possible. FNAC was performed on bilateral testis and cytological smears stained with Giemsa were then evaluated for spermatogenesis. *Results:* Of the 50 cases, maturation arrest was found to be the most common cytological pattern encountered (46%) followed by Sertoli cell only syndrome (28%). Varicocele was the most common clinical condition associated with infertility (12%). *Conclusion:* The purpose of this article was to review the role of testicular fine needle aspiration cytology in male infertility and interpret the results for evaluation of spermatogenesis.

Keywords: Spermatogenesis; Azoospermia; Cytological diagnosis; Testicular FNA.

How to cite this article:

Kaneeka Bhatnagar, Pavneet Kaur, Vikram Narang. Spectrum of Testicular FNAC in Infertile Males : A Study of 50 Cases in a Tertiary Medical Centre in North India. Indian J Pathol Res Pract. 2019;8(4):443-448.

Introduction

Infertility is defined as the inability of a sexually active, non-conceiving couple to achieve

pregnancy in one year [1]. Azoospermia is a major problem and is encountered in less than 2% of all men and 15% of infertile men and is defined as the complete absence of mature spermatozoa

from the ejaculate after the centrifuged semen has been assessed twice on at least two occasions [2]. This condition encompasses a variety of testicular alterations at the pretesticular, testicular and post-testicular level. Pretesticular causes include the endocrine abnormalities that adversely affect spermatogenesis. Testicular etiologies involve intrinsic disorders of spermatogenesis which are seen in conditions such as varicocele-induced testicular damage, undescended testis, testicular torsion, mumps orchitis, gonadotoxic effects of drugs, genetic abnormalities and idiopathic causes. The post-testicular causes of azoospermia include obstruction of the ductal system at any location of the male reproductive tract [3]. Thus, normal spermatogenesis is seen in obstructive azoospermia while hypospermatogenesis, maturation arrest and Sertoli cell only syndrome are representative of defective spermatogenesis are encountered in non-obstructive azoospermia [4]. Assessment of spermatogenesis is a crucial step in the diagnostic protocol of male infertility. Testicular biopsy is often regarded as the gold standard in evaluation of male infertility, however, fine needle aspiration cytology (FNAC) is gaining popularity as the alternative method owing to it being a simple, inexpensive and minimally invasive procedure. Both the methods allow a rational choice for the future management of the couple by reconstructive surgery, hormonal therapy, assisted reproduction or adoption [2].

The present study aims to evaluate the various cytological patterns in azoospermic males by testicular fine needle aspiration cytology (FNAC).

Material and Methods

This study was conducted in the Department of Pathology, Dayanand Medical College and Hospital, Ludhiana wherein 50 men presenting with primary or secondary infertility were referred for testicular FNAC. The subjects who fulfilled the criteria of infertility (both primary and secondary) and were azoospermic on semen analysis on at least two occasions were a part of the study. The ones whose semen analysis showed oligospermia or normal sperm count were excluded. Proper history of the patient along with relevant clinical details were noted. FNAC of the testis was done after taking proper consent explaining the procedure, and possible complications. Patients were then subjected to a fine needle aspiration of bilateral testes under local block for cytological evaluation under standard protocol. The scrotal skin was cleaned and spermatic cord block was achieved

by 5 to 7 ml of two percent lidocaine. Then the testis was positioned with epididymis and vas deferens directed posteriorly, safe from injury. The scrotal skin was stretched over the testes by wrapping the skin behind the testes with a gauze piece. Testes was aspirated using 21–23 G needle with 10 ml–20 ml syringe attached to a Cameco handle aspirator. On an average 2–3 passes were made in each attempt, before calling it “scanty cellularity”. Precise gentle in and out movement was done. Usually a thread like material, mixed with blood was aspirated. The smears were air dried, fixed in methanol, and stained by Giemsa. The aspirate was considered to be adequate when at least 2000 cells or 100 clusters of 20 cells each were obtained. The percentage populations of Sertoli cells and various spermatogenic cells, including spermatogonia, primary spermatocytes, spermatids, and spermatozoa, were calculated. Different cells in FNA smears were recognized by their nuclear and cytoplasmic characteristics. Based on the percentages obtained, a morphologic diagnosis of normal spermatogenesis, Sertoli cell only syndrome, hypospermatogenesis, maturation arrest and atrophic pattern was given.

Results

The mean age of the patients studied was 30.1 years ranging from 23 years to 44 years. The duration of infertility of the patients studied ranged from 1 year to 11 years with a mean duration of 3.94 years. Almost all patients had primary infertility except for 1 patient who had secondary infertility. A total of 50 FNACs were done, of which three patients had unilateral testis because of herniotomy, torsion of testis and primary testicular failure due to mumps respectively. The cytological diagnosis were given depending upon the percentage of different cells counted. Smears from aspirates with “Normal spermatogenesis” were cell rich having all cells of spermatogenic series seen as spermatogonia, spermatocytes, spermatids and spermatozoa along with Sertoli cells [Fig. 1]. Spermatozoa predominated the smear with 10–20 spermatozoa per high power field. This pattern was seen in 10% (n=5) of the cases. Smears which were labelled as having “Hypospermatogenesis” showed a relative decrease in all germ cell types as compared to the normal spermatogenesis. Overall paucity of spermatogenic cells was seen with representation of all germ cells including spermatogonia, spermatocytes, spermatids and spermatozoa. The spermatozoa were markedly reduced or were absent. 12% (n=6) of the total cases belonged to this

category. Smears which showed mainly Sertoli cells with no cells of spermatogenic series were given the cytological diagnosis of "Sertoli cells only/ Germ cell aplasia" and constituted the second most common pattern encountered in the study with 28% (n=14) of the total cases [Fig. 2]. Maturation arrest which constituted the maximum cases in the study can be divided into early maturation arrest and late maturation arrest. In Early maturation arrest (premeiotic) smears were cellular and showed a high percentage of spermatogonia and primary spermatocytes with absence of spermatids and spermatozoa. It comprised 6% (n=3) of all the cases in the study. Smears with Late maturation arrest

(Post meiotic), were characterized by a significant increase in proportions of round and elongated spermatids along with spermatocytes and Sertoli cells, but spermatozoa were absent or occasionally seen [Fig. 3]. This pattern was predominant in the study constituting upto 40% (n=20) of all cases. Smears which were scantily cellular and showed mainly proteinaceous material with few sertoli and leydig cells were labelled as "Atrophic" and comprised 4% (n=2) of all the cases. Of the 50 cases studied, maturation arrest was the most common cytological pattern accounting for 46% (n=23) of all cases with Atrophic pattern being the least frequent pattern encountered with 4% (n=2) of all cases.

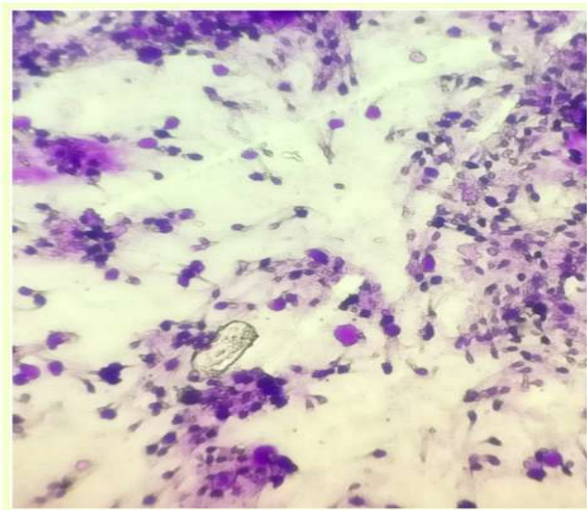


Fig. 1: FNAC smears of Normal spermatogenesis showing numerous spermatozoa seen in this field. (Giemsa, 400X)

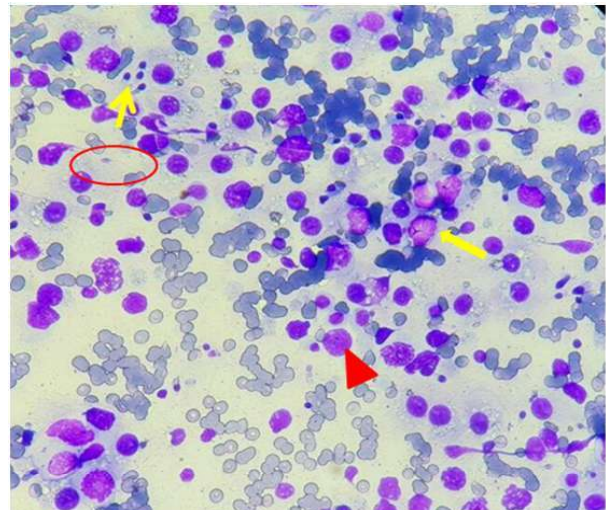


Fig. 3: FNAC smears of Late Maturation Arrest with predominance of spermatids (marked with yellow arrow) alongwith spermatocytes (marked with thick yellow arrow) and Sertoli cells (marked with red arrowhead). An occasional spermatozoa can be seen (in red circle). (Giemsa, 400x)

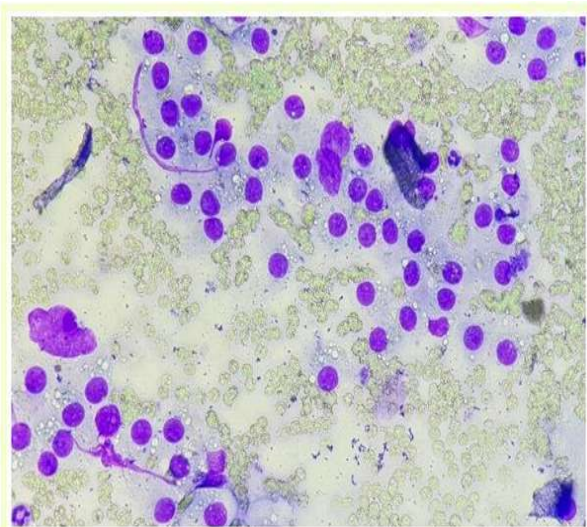


Fig. 2: FNAC smears of Sertoli cell Only Syndrome showing predominance of Sertolicells. (Giemsa, 400X)

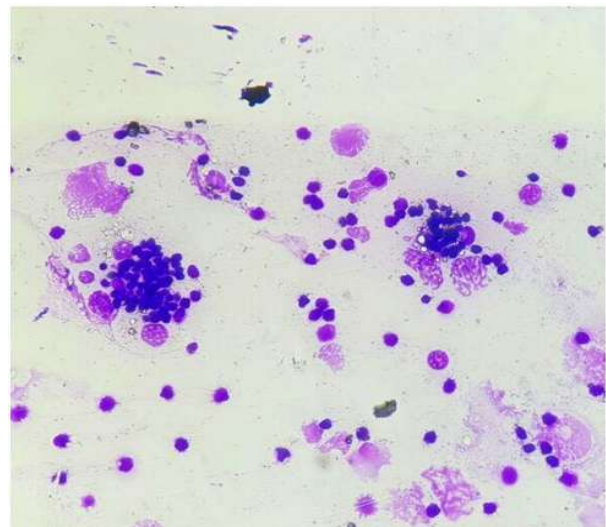


Fig. 4: FNAC smears showing presence of spermiophages ingesting spermatozoa and spermatids. (Giemsa, 400x)

The medical conditions that directly or indirectly led to infertility were documented in approximately half of the patients accounting for 54% (n=27) of all the cases. Varicocele was the most common clinical condition affecting 12% (n=6) of the patients, with bilateral varicocele seen in 2 patients while 4 having unilateral varicocele. Bilateral small testis was the second most common condition encountered in 8% of cases (n=5). Co-existing Tuberculosis was seen in one of the patients with bilateral small testis. Hydrocele (bilateral as well as unilateral) was noted in 6% (n=3) of patients, of which one patient was diagnosed with microfilaria on aspiration. History of prior surgery, tuberculosis, drug abuse, were among the other conditions that were documented (Table 1).

Hormonal profile was done in 28 patients (56%) which documented raised levels of both Serum FSH and Serum LH in 5 patients, of which 2 patients had Sertoli cell Only syndrome and

rest were diagnosed as having late maturation arrest, hypospermatogenesis and atrophic smear pattern respectively. High levels of Serum FSH only were noted in two more cases of Sertoli cell only syndrome, however, Serum LH levels were borderline high in one case while it was not done in the other patient. Rest of the patients showed a normal hormonal profile (Table 2).

Cytological correlation between findings of left and right testis was seen in 90% of the 50 cases analysed in the present study. Discordant findings were however, seen in five cases (10%). Late maturation arrest of one sided testis was seen in 4 of these 5 cases with the contralateral testis displaying obstructive azoospermia with presence of spermiphages in 2, microfilaria in 1 and normal spermatogenesis in 1 case. The fifth case showed normal spermatogenesis of one side with unsatisfactory hemorrhagic smears of the other side.

Table 1: Medical conditions associated with azoospermia

S. No	Condition	No. of cases	Percentage
1.	Varicocele	6	12%
2.	Bilateral Small testis	4	08%
3.	Drug abuse/desi medication	3	06%
4.	Tuberculosis	3	06%
5.	Hydrocele	3	06%
6.	Ductal cysts in ejaculatory duct or epididymis	2	04%
7.	Inguinal Hernia	2	04%
8.	Primary testicular failure due to mumps	1	02%
9.	Bilateral orchitis	1	02%
10.	None	25	50%

Table 2: Significant levels of S. FSH and S. LH alongwith cytological diagnosis

Cytological Diagnosis	S. FSH (1.4-18.1) IU/L	S. LH (1.5-9.3) IU/L
Sertoli cell syndrome (n=4)	27.63 24.02 21.2 48.9	9.23 22.13 15.75 -
Hypospermatogenesis (n=1)	36.9	13.37
Maturation arrest (n=1)	23.2	11.52
Atrophic (n=1)	60.65	18.55

Table 3: Comparison of various studies

	Maturation arrest	Hypospermat- ogenesis	Sertoli cell only syndrome	Normal Spermatoge- nesis	Atrophic
Present study (2017)	46.0%	12.0%	28.0%	10.0%	4.0%
Thiagarajan <i>et al.</i> (2016)	49.0%	14.30%	9.60%	11.90%	9.60%
Ahamad <i>et al.</i> (2014)	55.5%	12.96%	9.26%	11.11%	00%
Al-Dabbagh <i>et al.</i> (2012)	58.2%	5.9%	10.4%	17.9%	7.4%
Adhikari (2009)	6.1%	10.1%	46.4%	27.3%	10.1%
Agarwal <i>et al.</i> (2004)	11.6%	23.8%	21.2%	34.8%	6.4%
Kurien <i>et al.</i> (2003)	11.7%	15.3%	3.6%	12.6%	50.5%

Discussion

Azoospermia is present in about 10.0–15.0% of men evaluated for infertility. The assessment of male fertility mainly relied upon semen analysis and histological examination of testicular biopsies which were the accepted methods [5].

In 1965 and 1971, Obrant and Persson and Persson et al described the fine needle aspiration cytology method for obtaining material for cytological evaluation of spermatogenesis. The cytological features of seminiferous epithelium was described in detail by Schenck and Schill. However, the technique was generally ignored due to limited awareness of the technique and lack of diagnostic expertise [6]. Compared with testicular biopsy, which is more invasive and painful, and requires special clinical setting, FNA is a more rapid and minimally invasive procedure for evaluating spermatogenesis and can be easily done as an office procedure leading to significant cost reduction. Presence of mature spermatozoa in aspirates is significant as it provides a hope for biologic fatherhood either by in vitro fertilization (IVF), or by surgical correction of any obstruction at the vaso-epididymal junction, eliminating unnecessary and useless medical treatment in such cases [7].

In our study, 90% of the cases showed concordance between cytological findings of left and right side which is similar to studies done by Kurien *et al.*, Al-Dabbagh *et al.* and Thiagarajan *et al.* [8,2,9]. However, the heterogeneity of the spermatogenetic process within the testis as well as between two testes requires sampling of both testes and multiple puncture.

Maturation arrest was the most common cytological pattern seen in corroboration with studies done by Ahamad *et al.*, Dabbagh *et al.* and Thiagarajan *et al.* [10,2,9]. However, Sertoli cell only syndrome was the the commonest cytological diagnosis in azoospermic males in the study done by Adhikari [5] in 101 patients. In contrast, normal spermatogenesis was the most common finding in studies done by Agarwal *et al.* [11] and Kurien *et al.* [8] who documented obstructive azoospermia as the most common etiology for infertility [Table 3].

Jashnani et al. in their study suggested spermiphages as form of activated macrophages that ingest sperm heads with antigenic components in them and transport them to the basal capillaries which leads to formation of autoantibodies against the spermatozoa [12]. In our study, 2 patients with azoospermia showed spermiphages on testicular FNAC, thus correlating with the hypothesis [Fig. 4].

Serum FSH is a surrogate marker for spermatogenic function and our study showed that high levels are seen in patients with major spermatogenic defects. High values were seen in sertoli cell only syndrome, hypospermatogenesis and maturation arrest and was supported by a study done by Bettella *et al.* [4].

Varicocele was the most common clinical condition seen in our study and it was reaffirmed by studies done by Kurien *et al.* and Yadav *et al.* [8,13]. The adverse effect of varicocele on spermatogenesis is due to an increased testicular temperature, increased intratesticular pressure, hypoxia due to attenuation of blood flow, reflux of toxic metabolites from the adrenal glands and hormonal profile abnormalities [14].

Testicular biopsy was not a part of our study, but a similar study done on 57 infertile males in a different hospital in the same city showed a strong cyto- histological correlation in 91.9% of the cases when they were evaluated by both testicular FNAC as well as biopsy [8].

Testicular FNAC is a simple, minimally invasive procedure that is well tolerated by the patient. The testicular tissue is well preserved that helps in assessment of spermatogenesis. It also helps in characterization of specific cytological diagnosis that are related to the nature of testicular damage, such as Sertoli cells only syndrome, hypospermatogenesis and maturation arrest. Various studies have shown a strong cytological and histological agreement between findings of testicular FNAC and biopsy, thus making testicular FNAC as a reliable and faster method for management of azoospermic patients.

Moreover, a more comprehensive approach which includes detailed clinical history, semen analysis and good cytopathological assessment on a satisfactory smear will help to tailor the best management for the patient.

References

1. Zegers-Hochschild F, Adamson GD, Mouzon J *et al.* International Committee for monitoring assisted reproductive technology (ICMART) and the World Health Organisation (WHO) revised glossary of ART terminology. *Fertil Steril.* 2009;92:1520–24.
2. Al -Dabbagh, Ahmed AAD, B. Sh. Testicular Fine Needle Aspiration Cytology versus Open Biopsy in the Evaluation of Azoospermic Men. *Open Journal of Urology.* 2015;5:133–41.
3. Cocuzza M, Alvarenga C, Pagani R. The epidemiology and etiology of azoospermia. *Clinics* 2013;68:15–26.

4. Bettella A, *et al.* Testicular fine needle aspiration as a diagnostic tool in non-obstructive azoospermia. *Asian J Androl* 2005;7:289-94.
5. Adhikari RC. Testicular fine needle aspiration cytology in azoospermic males. *Nepal Med Coll J* 2009;11: 88-91.
6. Ahamad MSU, Chowdhary BO, Zohair Mohd. Testicular fine needle aspiration in male infertility: A review. *JMCTA mini reviews*. 2010;21:62-5.
7. Ibrahim KS. Assessment of spermatogenesis by fine needle aspiration of testes in patients with azoospermia. *Ann Coll Med Mosul*. 2013;39:143-6.
8. Kurien A, Mammen K, Jacob S. Role of fine needle aspiration cytology (FNAC) of testes in male infertility. *Indian J Urol*. 2003;19:140-4.
9. Thiagarajan R, Balaji A, Vetrichandar *et al.* A Study on the Role of Fine Needle Aspiration Cytology of Testes in Azoospermia. *IOSR-JDMS*. 2016;15;1-4.
10. Ahamad MSU, Islam JS, Chowdhary BO. Testicular FNAC in Azoospermia. *Chatt Maa Shi Hosp Med Coll J*. 2014;13:46-8.
11. Agarwal MS, Gupta A, Chaturvedi K, Lavania P. Assessment of the utility of testicular FNAC in infertile males with special reference to differential counts. *Indian J Urol*. 2004;20:148-53.
12. Jashnani K, Desai H, Shetty J. Spermiphages on testicular fine needle aspiration cytology: A rare finding. *DiagnCytopathol*. 2016;44:232-4.
13. Yadav SP, Gopal M, Chadha I, *et al.* Comparative evaluation of the needle aspiration cytology and biopsy of testis in diagnosis of male infertility. *J Indian Med Assoc*. 1997;95:129-34.
14. Kantartzi PD, Goulis CD, Goulis GD, Papadimas I. Male infertility and varicocele: myths and reality. *Hippokratia*. 2007;11:99-104.